

# REPRODUCTIVE SYSTEM BREAST (MAMMARY GLAND)

CN: Use yellow for E; pink or tan for K, and a similar but darker color for J; and light colors for A, D, and G. (1) Color the two illustrations of the breast and underlying breast structures together. (2) Color the arrows indicating the direction of lymph flow and the lymph nodes of the chest. Note network of lymph vessels. (3) Color the diagrams of breast development. (4) Color the enlarged view of glands and ducts in the lower right corner.

## BONE

RIB<sup>A</sup>  
CLAVICLE<sup>A'</sup>

## MUSCLE & FASCIA

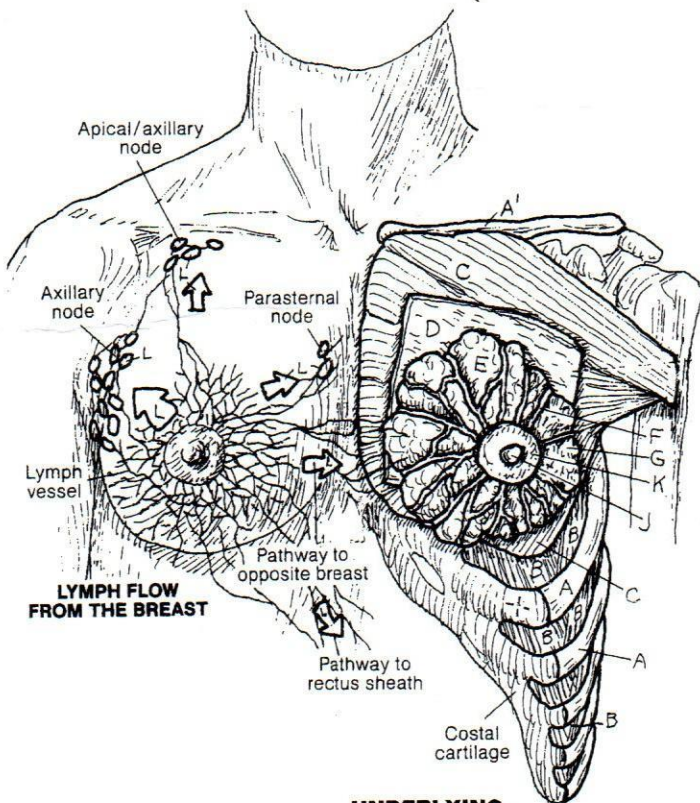
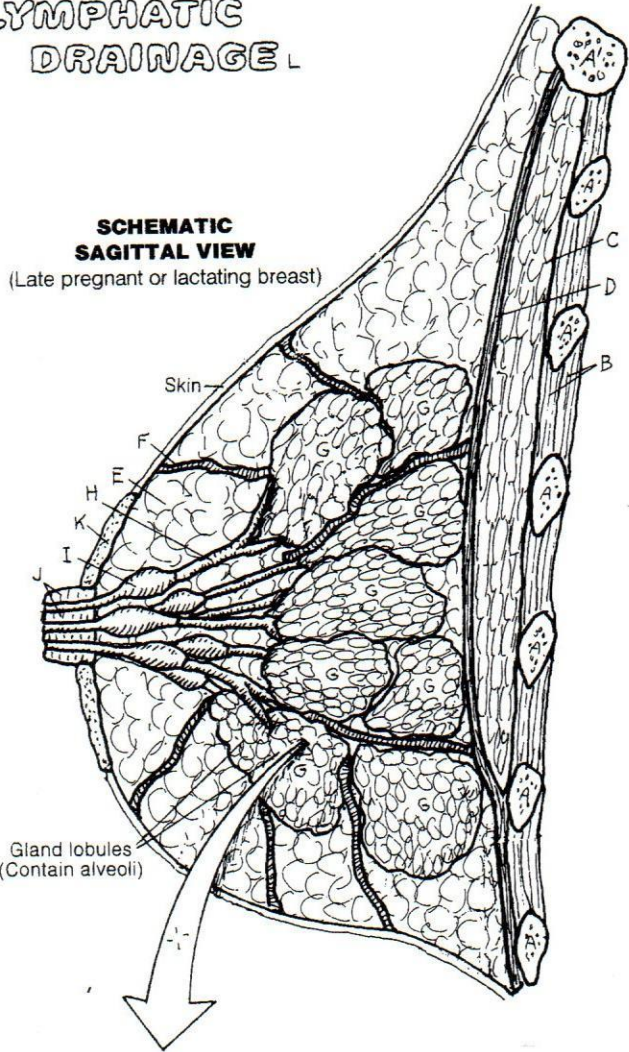
INTERCOSTAL MUSCLE<sup>B</sup>  
PECTORALIS MAJOR MUSCLE<sup>C</sup>  
DEEP FASCIA<sup>D</sup>

## BREAST

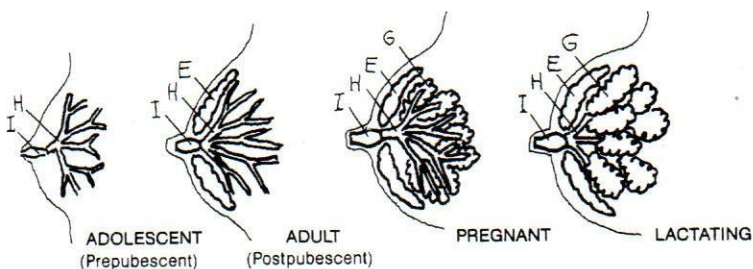
SUPERFICIAL FASCIA (FAT)<sup>E</sup>  
SUSPENSORY LIGAMENT<sup>F</sup>  
GLANDULAR LOBE<sup>G</sup>  
LACTIFEROUS DUCT<sup>H</sup>  
LACTIFEROUS SINUS<sup>I</sup>  
NIPPLE<sup>J</sup>  
AREOLA<sup>K</sup>

## LYMPHATIC DRAINAGE<sup>L</sup>

**SCHEMATIC  
SAGITTAL VIEW**  
(Late pregnant or lactating breast)



**UNDERLYING  
BREAST STRUCTURE**  
(Postpubescent, nonpregnant,  
nonlactating)



**BREAST DEVELOPMENT**

