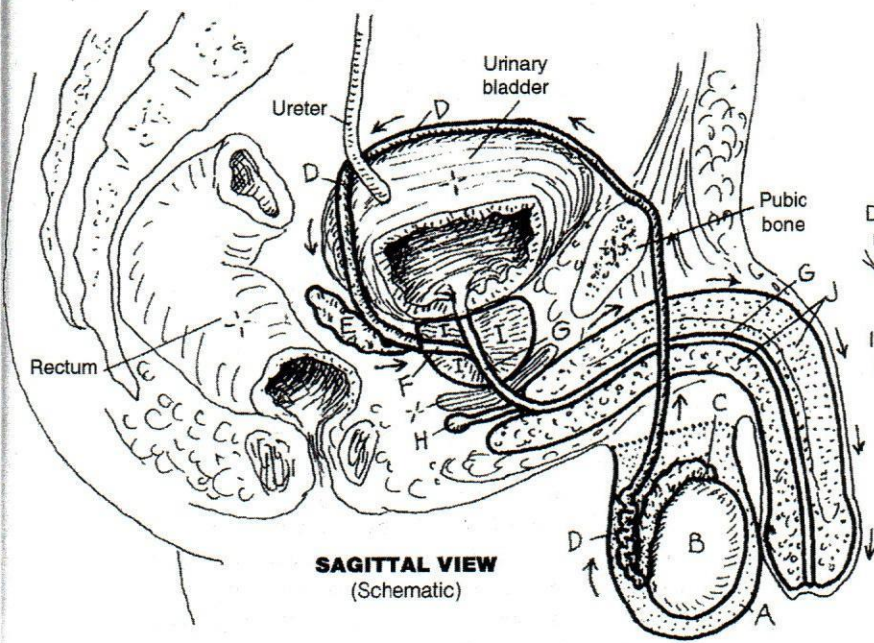
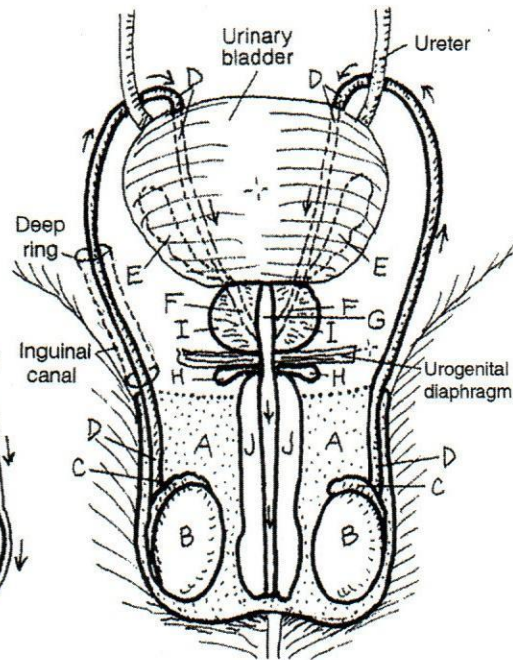


- SCROTUM **A**
- TESTIS **B**
- EPIDIDYMISS **C**
- DUCTUS DEFERENS **D**
- SEMINAL VESICLE **E**
- EJACULATORY DUCT **F**
- URETHRA **G**
- BULBOURETHRAL GLAND **H**
- PROSTATE GLAND **I**
- PENIS **J**

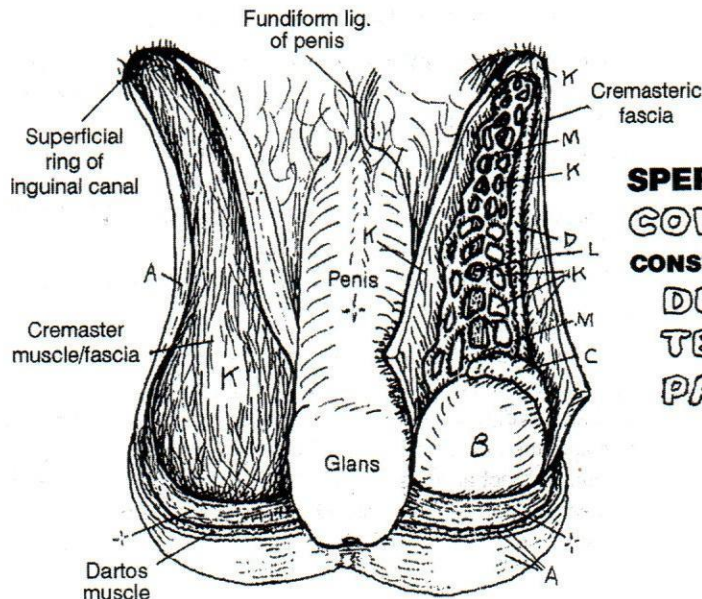
**CN:** Use red for L, blue for M, and very light colors for A, J, and K.  
(1) Color the composite sagittal and composite coronal section/  
anterior views together. (2) Color the anterior view below; be  
especially observant while coloring the dissected view of the  
coverings and constituents of the spermatic cord.



**SAGITTAL VIEW**  
(Schematic)



**ANTERIOR VIEW**  
(Schematic)



**ANTERIOR VIEW OF SCROTUM**  
(With cord dissected)

**SPERMATIC CORD** (See page 49)

**COVERINGS **K****

**CONSTITUENTS**

- DUCTUS DEFERENS **D**
- TESTICULAR ARTERY **L**
- PAMPINIFORM
- VENOUS PLEXUS **M**